

Endothelial Keratoplasty in Challenging Cases

Jacqueline Beltz, FRANZCO

Massimo Busin, MD

Amit Patel, FRCOphth

Vincenzo Scorcia, MD

Instruction Course ESCRS September 8th 2012

Endothelial Keratoplasty in Challenging Cases

J. Beltz; M. Busin; A. Patel; V. Scorcia

Contact: jacquelinebeltz@mac.com

Instruction Course ESCRS September 8th 2012 1700 – 1800

Introduction

The indications for Endothelial Keratoplasty (EK) have rapidly expanded, to the point that this surgery is now appropriate for endothelial failure of almost any etiology. More and more surgeons are switching to EK, as penetrating keratoplasty (PK) provides unacceptably high intra-operative and post-operative risk, as well as slow visual recovery and an unpredictable amount of induced astigmatism.

As the indications expand for EK, more and more challenging cases arise. With minor modification to the standard technique, EK is still possible in these cases, and provides perhaps even more advantage over PK for these higher risk cases.

Now that EK has become established, we strive towards faster and better visual results. Recent evidence has confirmed suspicions that thinner tissue is compatible with better visual outcome. For this reason, some surgeons prefer to perform Descemet Membrane Endothelial Keratoplasty (DMEK) for patients with endothelial failure, however, increased surgical difficulty, higher detachment rate, and limitations in eyes with more complex pathology render DMEK inadvisable for many of these more complex eyes. Ultra-Thin Descemet Stripping Automated Endothelial Keratoplasty (UT-DSAEK) is an alternative technique, by which we aim to achieve the visual results of DMEK, whilst maintaining the surgical ease of DSAEK, and this technique remains viable for most complex cases. Technique selection remains important on a case-by-case basis, as thinner tissue may not be necessary for a patient with significant ocular co-morbidities and therefore less than 20/20 visual potential.

We aim to provide some practical advice for those surgeons performing EK in their Institutions, and wishing to expand their practice to include more challenging cases.

Indications

Endothelial Keratoplasty is indicated for any form of endothelial failure. More challenging cases to be discussed in this course will include:

- Eyes with endothelial failure and cataract
- Phakic eyes
- Aphakic eyes
- Aniridic eyes
- Eyes with ACIOLs
- After filtering glaucoma procedures
- In long standing/severe corneal edema

Methods and instructions

DSAEK - Conventional Technique

Tissue Preparation – Normal thickness tissue (Note: assumes donor tissue of approximately 550µm thick. Technique may be modified for thicker or thinner donor tissue.)

1. Mount the tissue on artificial anterior chamber (AC)
 - a. Connect artificial AC to BSS bottle placed at 120 cm above AC
 - b. With fluid on, place tissue on AC
 - c. Turn off fluid
 - d. Place the cap, and tighten
 - e. Bend tubing, and open the fluid flow
 - f. Place plunger at 40 - 50cm from AC (or closer to ensure a thicker cut and thinner donor tissue)
 - g. Advance plunger, to stop fluid flow, and to increase pressure in AC
 - h. Observe 'blanching' of cornea, and ensure pressure is high
2. Cut the tissue
 - a. Using a 300µm cutting head, advance for at least 4 seconds
 - b. Reserve the anterior cap for a subsequent transplant
3. Mark Stromal side
 - a. Using trypan blue, mark circumference of cut
 - b. Mark 'F' on anterior surface
4. Remove the tissue
 - a. Bend tubing and open plunger (to prevent collapse, and endothelial damage)
 - b. Remove tissue from front
5. Punch tissue to desired diameter
 - a. Approximately 2mm less than vertical corneal diameter
 - b. Usually 8.5 – 9mm
 - c. To prevent incomplete punch, pull rim upwards, prior to removing trephine

Tissue Preparation – Ultra-Thin (again, assuming starting point of approx.. 550 µm)

1. Debulking Step

- a. Tissue mounted on artificial anterior chamber
- b. Bottle height 120cm above tissue
- c. Thickness of tissue measured
- d. System closed, clamp at approx. 50 cm
- e. Approx. 2/3 of anterior stroma removed, using 300µm or 350 µm cutting head, passed for at least 4 seconds
- f. Removed lamellar retained for subsequent case
- g. Thickness of residual stromal bed measured

2. Refinement Step

(Further removal of stroma)

- a. Tissue remains mounted on artificial anterior chamber
- b. Rotate the top of the chamber, or the tissue 180°
- c. If pachymetry $\leq 150 \mu\text{m}$, use 50 µm head
- d. If pachymetry 150 - 200 µm, use 90 µm head
- e. Pachymetry $> 200 \mu\text{m}$, use 130 µm head

- f. Bottle height remains same
- g. Close system by clamping at 50cm
- h. Advance the cutting head, slowly and smoothly (at least 6 seconds)
3. Mark Stromal side
 - a. Using trypan blue, mark circumference of cut
 - b. Mark 'F' on anterior surface
4. Enlarge the Diameter of the cut, if necessary
5. Remove the tissue
 - a. Bend tubing and open plunger (to prevent collapse, and endothelial damage)
 - b. Remove tissue from front
6. Punch tissue to desired diameter
 - a. Approximately 2mm less than vertical corneal diameter
 - b. Usually 8.5 – 9mm
 - c. To prevent incomplete punch, pull rim upwards, prior to removing trephine

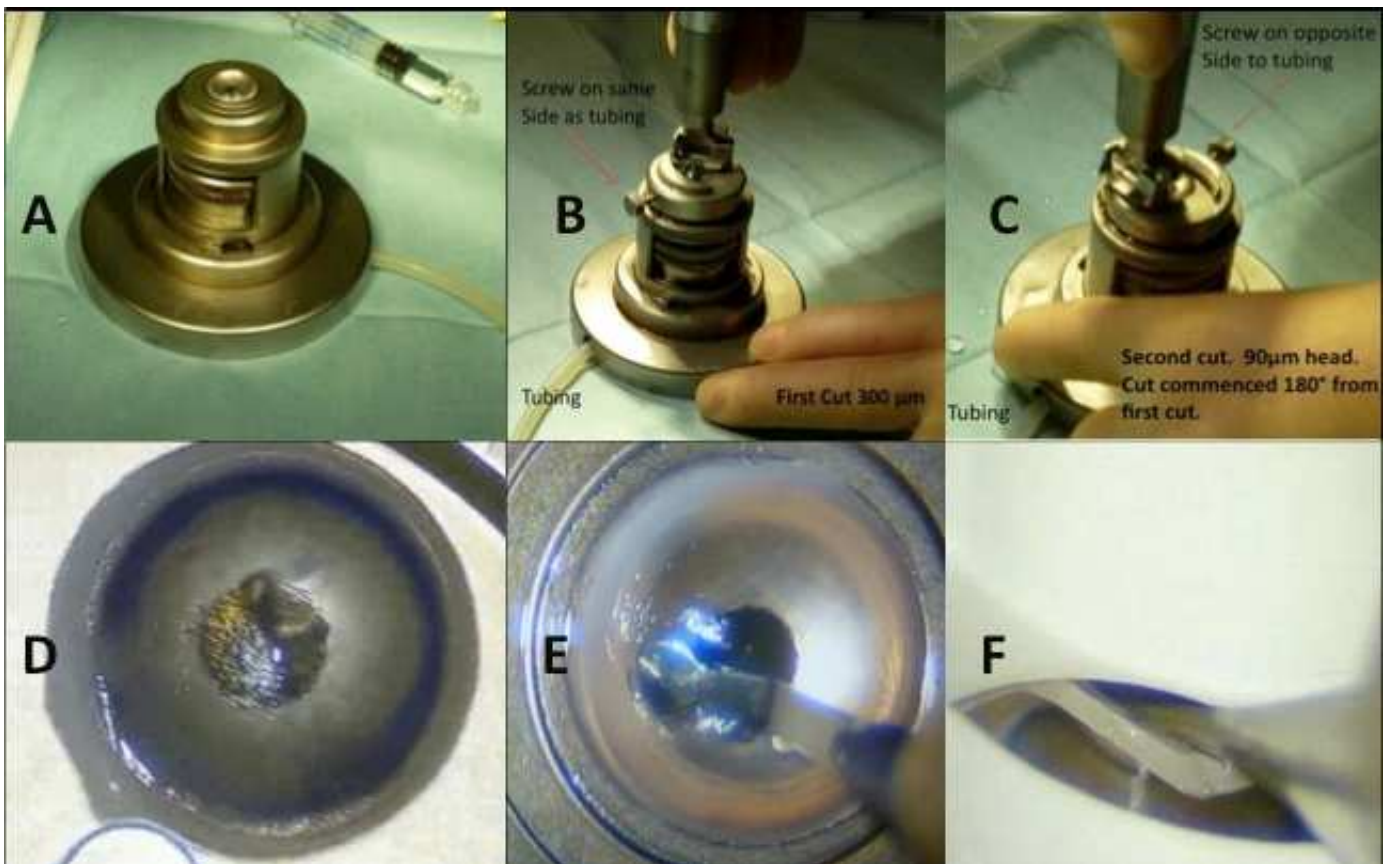


FIGURE Preparation of tissue for Ultrathin DSAEK. A) Tissue is mounted on a 3 piece Artificial AC B) Debulking step with 300 µm cutting head C) Top of artificial AC is rotated 180 degrees, and 2nd cut with 90 µm cutting head performed D) Periphery of Cut surface is marked with trypan blue, and an F placed on the anterior surface E) Diameter of cut surface enlarged if required F) Tissue is punched, with tissue rim lifted, to ensure complete penetration of the blade.

Surgery

1. Remove epithelium, if necessary, to improve visibility
2. Insert 25G needle at 12 o'clock (short, steep tunnel)
3. Remove some aqueous
4. Inject air
5. Bend needle (reverse cystotome), or use 'scorer'
6. Score DM and endothelium, to desired diameter (actual diameter not important, make sure visual axis clear)
7. Using blunt cannula or 'scorer' at 12 o'clock, or 'stripper' via a temporal paracentesis, mobilise endothelium and DM, and place near nasal limbus
8. Create steep, short clear corneal wound nasally (1.0mm length, 3.2mm width) and temporally (1mm width)
9. Remove stripped DM and endothelium using forceps
10. Enlarge superior wound to 1mm
11. Place AC maintainer into the superior paracentesis, with bottle placed at approx. 50 cm above eye
12. Create inferior peripheral iridotomy (vitreoretinal scissors)
13. Mount tissue onto glide
 - a. Place tissue on glide using forceps, or scoop onto glide if Ultra-thin
 - b. Center tissue on glide, and advance to tip
14. Insert tissue
 - a. Have AC maintainer on
 - b. Advance forceps through the temporal wound, across eye, and out of the nasal wound
 - c. Grasp tissue
 - d. Draw tissue into the eye
 - e. Allow tissue to open
 - f. Remove AC maintainer
15. Center tissue
 - a. Ballot cornea from surface
16. Inject air beneath tissue
17. Suture all wounds, air tight with 10-0 Nylon
18. Take a 30 G needle, via a long, peripheral tunnel, inject air beneath donor tissue, taking care to be in front of the iris, until complete fill is achieved
19. Orbital floor steroid and antibiotic

Post-operative management

1. Posture supine for 2 hours
2. Assess patient at slit lamp
 - a. Remove some air if air level fails to lie above iridotomy
3. Commence topical steroid and antibiotic
 - a. 2 hourly for 2 weeks
 - b. 3 hourly for 2 weeks
 - c. 4 x a day for 2 weeks
 - d. 3 x a day for 1 month
 - e. 2 x a day for 1 month
 - f. 1 x a day, for life, unless phakic/steroid responder

4. Review

- a. Day 1
- b. Day 2
- c. Day 3
- d. Week 1
- e. Month 1
- f. 3 monthly

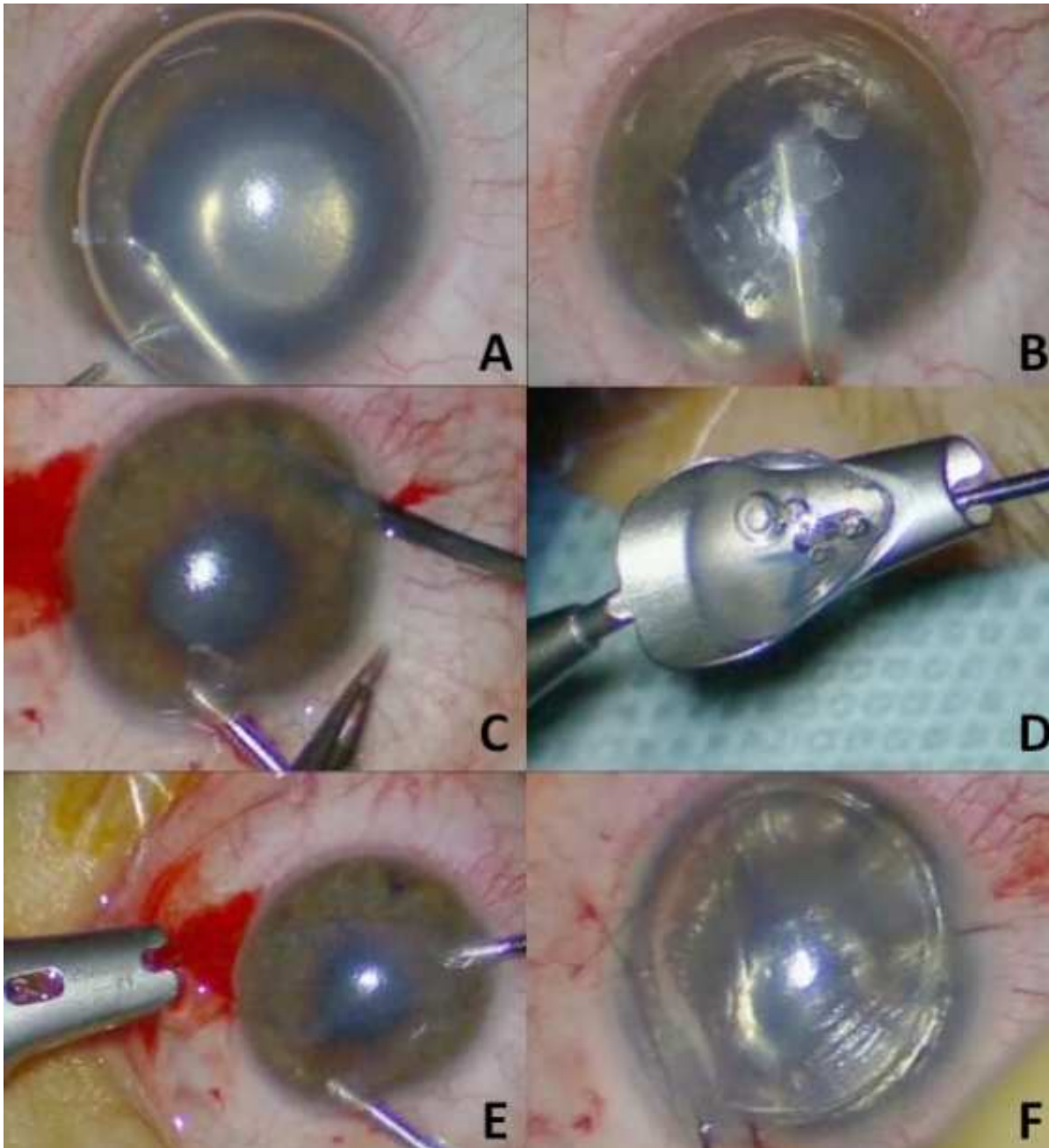


FIGURE Photographic representation of surgical steps of DSAEK. A) DM scored B) DM stripped C) PI created D) Tissue on glide E) Tissue inserted F) Wounds sutured and air injected.




FIGURE Steps involved in mounting UT-DSAEK tissue on glide.

DSAEK - Challenging Cases

1. Eyes with endothelial failure and cataract

DSAEK may be combined with cataract surgery, to constitute the *DSAEK triple procedure*. In these cases, cataract surgery should be performed first, by means of the surgeon's standard technique. Ideal modifications include capsulorhexis being performed under air, and IOL inserted by means of the AC maintainer, in order to completely avoid the use of viscoelastic. If the surgeon is not comfortable performing these manoeuvres, a cohesive viscoelastic device may be chosen, but complete removal must be ensured prior to the stripping of DM. An intra-cameral anticholinergic agent such as acetylcholine chloride may be used to constrict the pupil after the cataract surgery, and prior to the DSAEK. Wound placement is important, as the same wounds should be used for both cataract surgery and DSAEK. Again, wound placement must suit each individual surgeon, however, we recommend either sitting superiorly with the main wound nasally in the left eye and temporally in the right eye, or alternatively sitting superiorly with the main wound superiorly, or sitting temporally with the main wound temporally placed. Make sure to consider the hypermetropic shift secondary to EK on selection of the IOL. This can be expected to be in the order of 0.7 D for normal thickness tissue, and probably less for UT-DSAEK.

Summary – DSAEK Triple

- Avoid viscoelastics altogether, or use a cohesive device and make sure it is thoroughly removed
- Think about wound placement
- Constrict the pupil after cataract surgery
- Choose an IOL to render the patient slightly more myopic than would otherwise be the case

2. Phakic eyes

DSAEK may be appropriate in pre-presbyopic patients with endothelial failure. The risk of traumatic cataract may be reduced by placing the incisions slightly superiorly to their regular 9 and 3 o'clock positions. In this way, pass of the instruments across the exposed crystalline lens may be avoided during the introduction of the tissue.

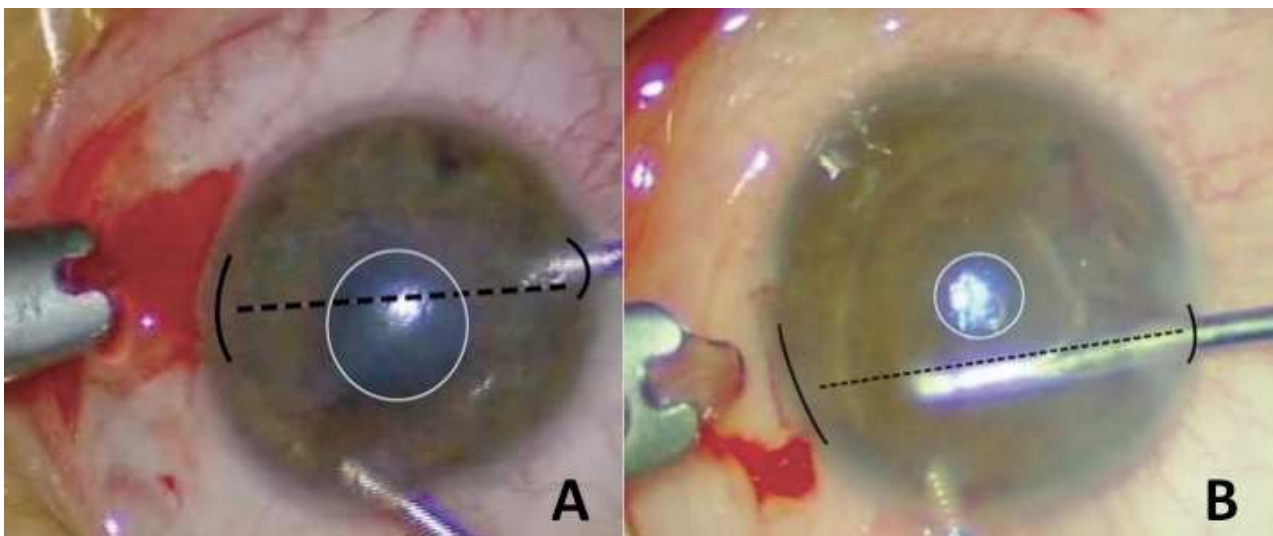
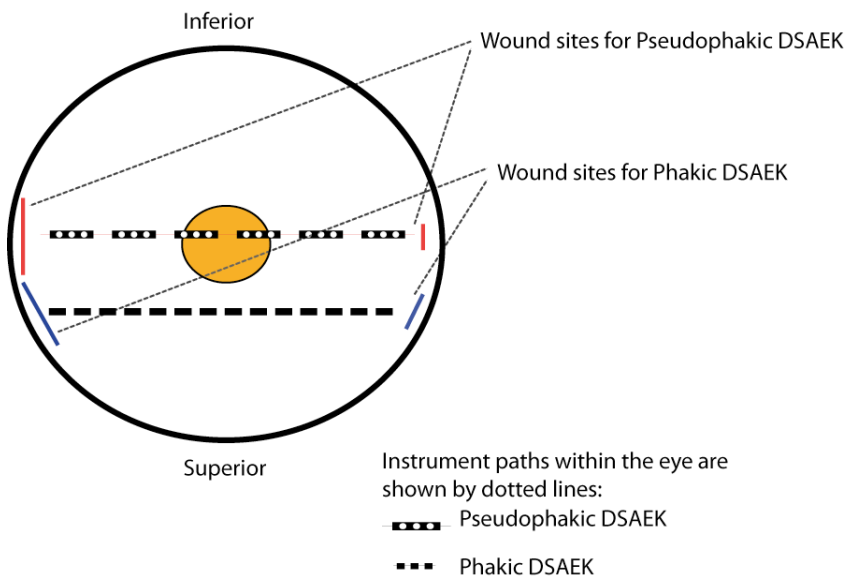


FIGURE . New wound position in phakic eyes A) usual wound positions B) new wound positions allow intraocular instruments to pass across the eye, without the risk of contact with the exposed crystalline lens.

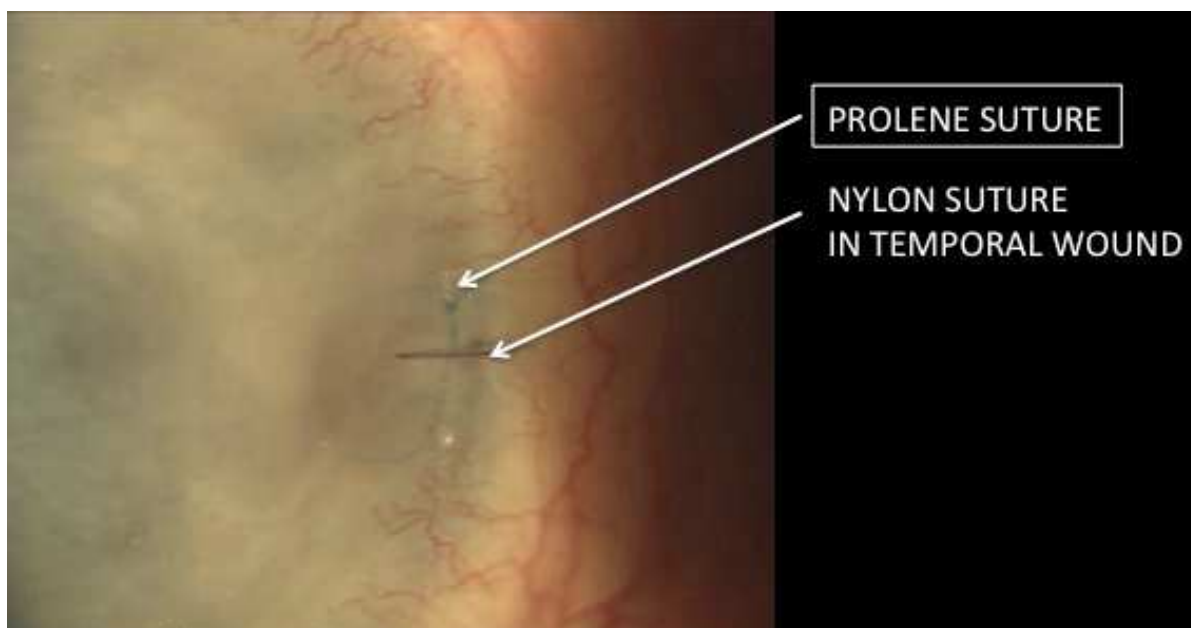
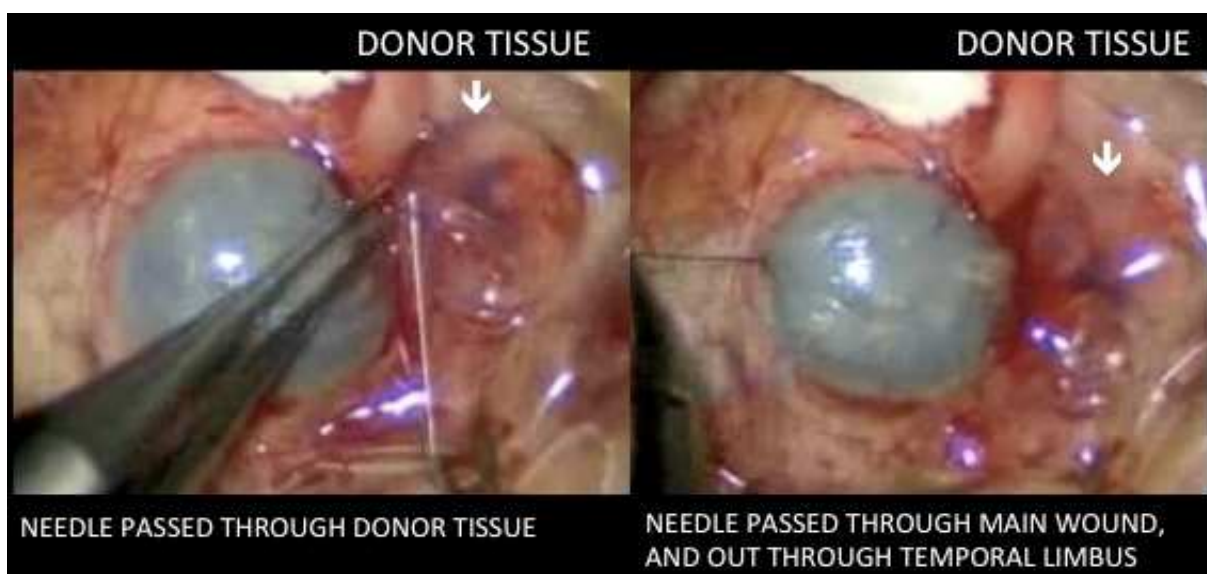
Summary – Phakic Eyes

- Shift wounds slightly superior to their usual 9 and 3 o'clock positions
- Avoid lenticular contact during formation of the PI
- Discontinue topical steroids after 6 months, if clinically appropriate

3. Aphakic eyes, aniridic eyes, or eyes with large iris defects

Eyes with absence of an adequate diaphragm between the anterior and posterior segments pose additional challenge, as we face the risk of the DSAEK tissue falling posteriorly, as well as being unable to identify whether or not the tissue is present or attached post-operatively. In these cases, or in cases with very poor visibility, a 10-0 prolene suture may be placed between the donor tissue and the host cornea.

For this technique, donor tissue should be placed endothelial side down on viscoelastic on the conjunctival surface, adjacent to the main wound. Both straight needles of a double ended 10-0 prolene suture are passed through the donor tissue, and then into the main wound, and out through the temporal limbus. Tissue may then be folded and pulled into the eye, or mounted on a glide and inserted in the normal way. After injection of air beneath the lenticule, the prolene suture may be tied off, providing at least one known position or point of attachment of the donor tissue in these eyes with poor visibility.



Summary – DSAEK with supporting suture for eyes with absence of a diaphragm between anterior and posterior segments, or in eyes with very poor visibility

- Use a 10-0 prolene suture to provide a single known point of position or attachment of the donor tissue within the eye
- In the case of a rebubble, insert the needle beneath this known point of attachment, to allow the donor tissue to rise up into position

4. Eyes with ACIOLs

Anterior chamber IOLs may be unstable within the anterior chamber, often contributing to the endothelial failure in the first place, and certainly resulting in high endothelial loss post EK. Any unstable ACIOL, whether of Kelman or Iris Claw type, should be removed and replaced with a posterior chamber IOL, sutured if necessary, whenever possible. This lens exchange may take place during the same surgery as the DSAEK.

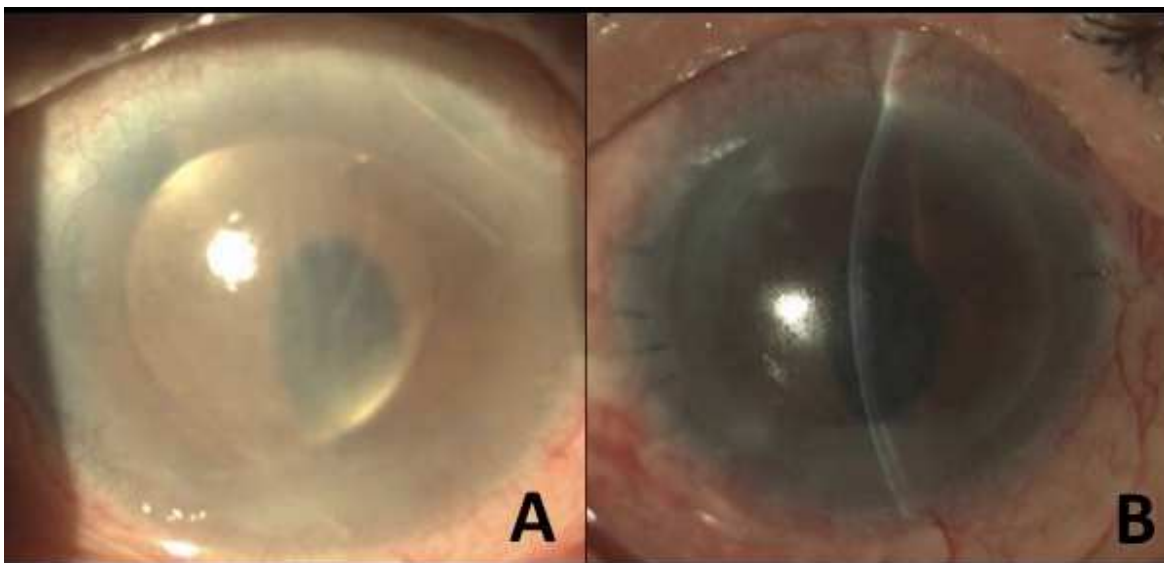


FIGURE. A) Preoperative appearance of patient with endothelial failure and ACIOL. B) Appearance of cornea 2 days following DSAEK and IOL exchange with sutured PCIOL.

5. Eyes with previous glaucoma filtering procedures

The main problem with EK in these eyes occurs during attempt to completely fill the eye with air at the end of the case. This is as a result of the air disappearing through the trabeculectomy or up the drainage device, instead of remaining in the anterior chamber.

We suggest the use of full thickness corneal venting incisions, as described by Francis Price, in these cases more likely to experience detachment. Other small modifications will also be discussed in the course presentation.

6. Post PK

DSAEK is highly successful as a treatment for failed PK, as it allows rapid recovery of vision, without the increased risk that occurs with re-do PK. We prefer to remove the DM from the original donor tissue, however, this step has been shown by other groups to be optional. Scoring should take place within the margin of the original PK, so as to not interfere with the wound edge. We prefer to implant a donor tissue of greater diameter than the original PK, in order to implant as many endothelial cells as possible, and also to provide a strong wound in the case of the patient requiring incisional correction of astigmatism following the procedure.

Detachment rates should not be higher than for DSAEK in the absence of previous PK, even in the presence of an internal lip, or wound irregularity, as long as the donor tissue is thin enough to be able to conform over the irregular area.

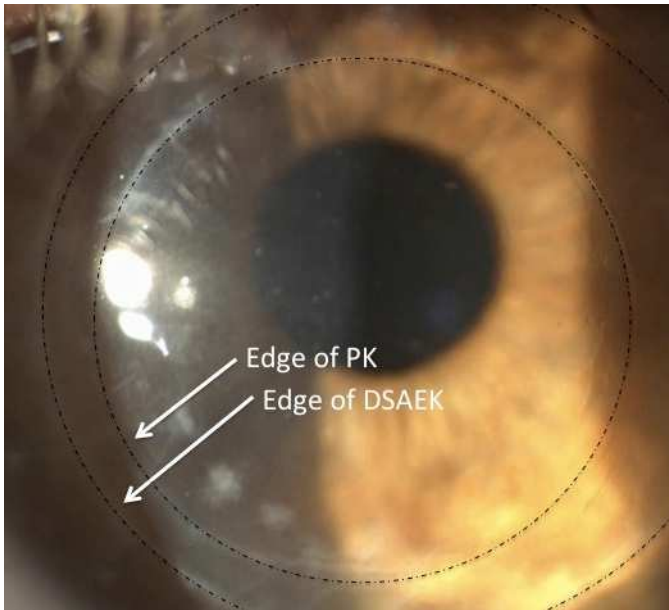


FIGURE Post operative appearance with schematic representation of PK and DSAEK grafts.

After DSAEK, if the DSAEK tissue that has been inserted is of larger size than the original PK, a relatively strong, top-hat type wound configuration exists. For this reason, full-thickness relaxing incisions may be performed in the original PK wound, in order to correct astigmatism, with reduced risk of wound leak or dehiscence.

Astigmatism correction may be done under topical anaesthesia. Corneal topography should be studied first, in order to identify the steep axis of the astigmatism. Next, a 15 degree blade is used to make an incision through the old PK wound, firstly on the side of the larger half of the bow-tie. One clock hour of the wound should be opened up, under observation via the intraoperative keratoscope. The same can then be done on the smaller side of the bow-tie. If this is not sufficient, the wound(s) can simply be enlarged, until the keratotomy shows that the oval has become round. The end point should be a slight under-correction, as the effect will increase in the first 2-3 days after surgery.

If the DSAEK graft inserted was smaller than the original PK, astigmatic keratotomy should be performed, inside the PK margin, and also inside the DSAEK margin, so that posterior support from the DSAEK lenticule is present.

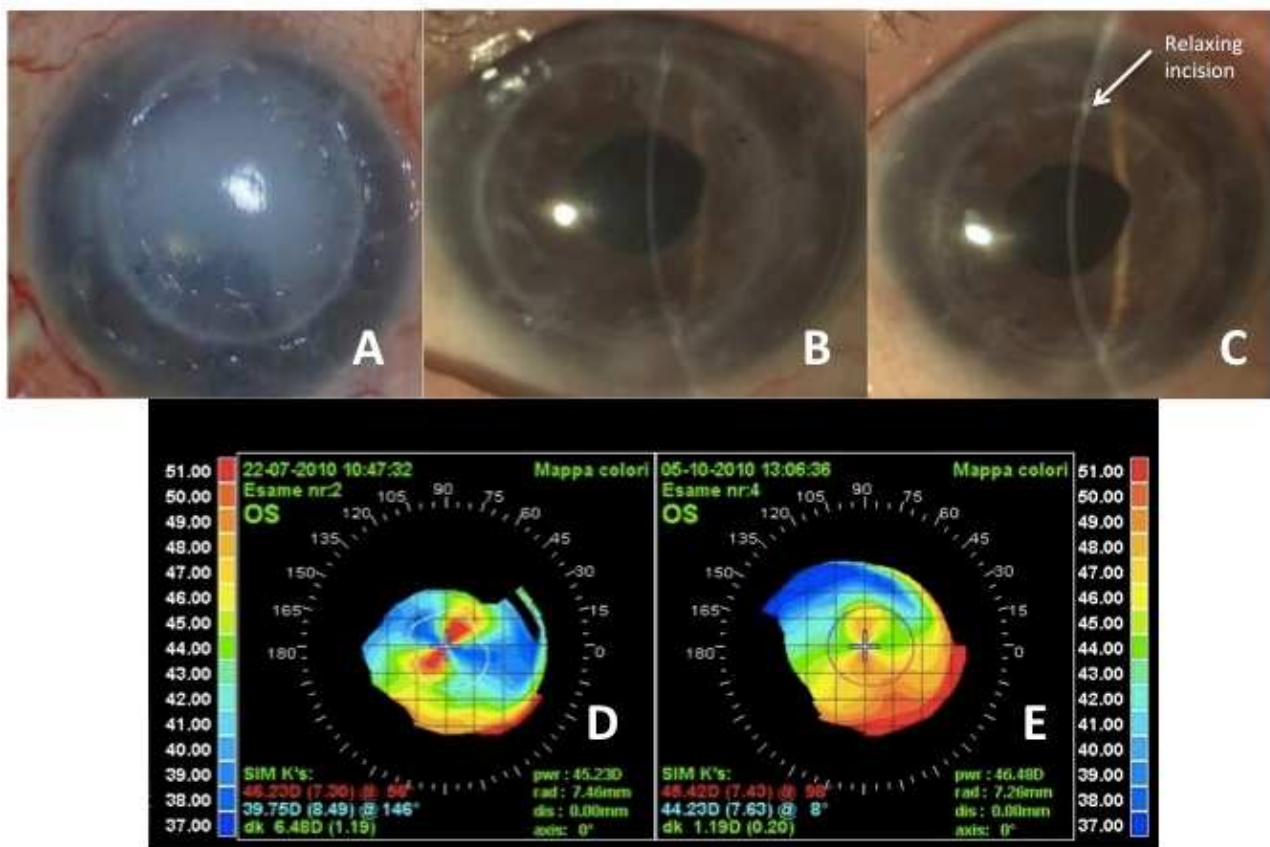


FIGURE. Astigmatism correction post DSAEK in PK. A) Preoperative appearance. B) 3 months post DSAEK in PK. C) 3 months post astigmatism correction. D) Corneal topography after DSAEK, note 6.48D of astigmatism. E) Corneal topography 3 months after relaxing incisions, showing significant reduction in astigmatism, to 1.19D.

Summary – DSAEK post PK

- Do not interrupt the original graft host junction during formation of the wounds
- Score and strip a smaller area than the original PK, taking care not to interfere with the graft-host junction
- Punch DSAEK donor tissue to a larger size than the original PK, usually 9.0mm
- Correct astigmatism post-operatively with full-thickness relaxing incisions in the original PK wound